

On the Detection of Retinal Vessels in Fundus Images

Bin Fang^{1,2}

Wynne Hsu^{1,2}

Mong Li Lee²

¹Singapore-MIT Alliance
National University of Singapore

²Department of Computer Science, School of Computing
National University of Singapore

Abstract—Ocular fundus image can provide information on pathological changes caused by local ocular diseases and early signs of certain systemic diseases. Automated analysis and interpretation of fundus images has become a necessary and important diagnostic procedure in ophthalmology. Among the features in ocular fundus image are the optic disc, fovea (central vision area), lesions, and retinal vessels. These features are useful in revealing the states of diseases in the form of measurable abnormalities such as length of diameter, change in color, and degree of tortuosity in the vessels. In addition, retinal vessels can also serve as landmarks for image-guided laser treatment of choroidal neovascularization. Thus, reliable methods for blood vessel detection that preserve various vessel measurements are needed. In this paper, we will examine the pathological issues in the analysis of retinal vessels in digital fundus images and give a survey of current image processing methods for extracting vessels in retinal images with a view to categorize them and highlight their differences and similarities. We have also implemented two major approaches using matched filter and mathematical morphology respectively and compared their performances. Some prospective research directions are identified.

I. INTRODUCTION

Ocular fundus image can provide information on pathological changes caused by local ocular diseases and early signs of certain systemic diseases, such as diabetes and hypertension. For example, central retinal artery occlusion usually causes generalized constriction of retinal arteries, while central retinal vein occlusion typically produces dilated tortuous veins, arteriosclerosis can cause arteries to acquire a copper or silver color. Hypertension may result in focal constriction of retinal arteries, and diabetes can generate new blood vessels (neovascularization). Analyzing and interpreting retinal images have become a necessary and important diagnostic procedure in ophthalmology and considerable research effort has been devoted to automate this process. Among the features in ocular fundus image, the structure of retinal vessels plays an important role in revealing the state of diseases [1]. In addition, blood vessels can also serve as landmarks for image-guided laser treatment of choroidal neovascularization [2]. Thus, reliable methods of vessel detection that preserve various vessel measurements are needed.

Diabetic retinopathy is a complication of diabetes mellitus. It is the most common cause of blindness worldwide [3-9]. Although diabetes itself cannot be prevented, complications such as blindness can be moderated if the disease is diagnosed early. The most effective method currently is regular screening of the fundus to detect early signs of diabetic retinopathy [10]. Microaneurysms – tiny dilations of the blood vessels - are the first unequivocal sign of diabetic retinopathy so that their detection in fundus images through photography might be enough to detect the disease in an early stage. However, with a large number of patients undergoing regular screenings, tremendous amount of time is needed for the medical professionals to analyze and diagnose the fundus photographs. By automating the initial task of analysing the huge amount of retinal photographs for symptoms of diabetic retinopathy, the efficiency of the screening process can be greatly improved. At the same time, patients that require the attention of the ophthalmologist would be timely referred.

On the other hand, diabetic retinopathy resulting from long-term diabetes mellitus is one of the common diseases that lead to choroidal neovascularization (CNV). CNV is an important condition that leads to blindness. It decreases the amount of blood supplying the retina especially within the central area of acute vision [11]. One treatment strategy is the use of lasers to photocoagulate the affected areas of the retina. To obtain satisfactory results, the physician must identify the full extent of CNV and cauterize it completely [11]. Care must be taken to avoid radiating the macula (the area of acute vision), optic disc, and major blood vessels [12].

In the analysis of fundus images, two different types of the fundus images are used in term of the image capture procedure: retinal angiographies and normal fundus images. Images of retinal angiographies are obtained after an injection of fluorescein into the patients' arm. Retinal vessels are highlighted using an ultraviolet light. Photographs taken during the 5-min injection represents brighter blood vessels relative to a darker background (i.e., reversed contrast). The normal images are acquired using a fundus camera applied directly to the retina. In these images, the vessels are less contrasted than in angiographic images and they contain less information: small vessels are not obvious in the image. However, they are still very precise in accordance with the

information contained in the image and widely used in retinal image analysis.

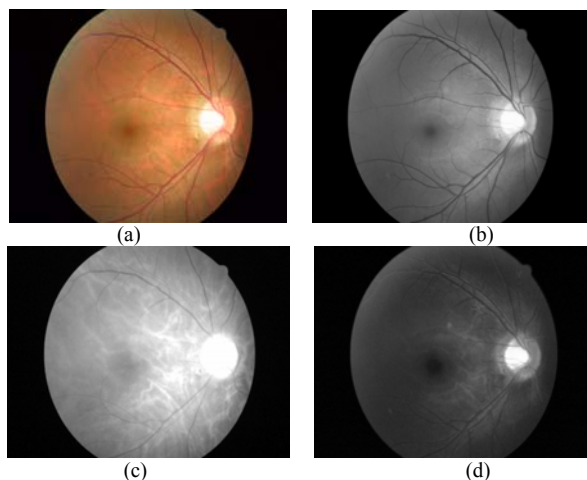


Fig. 1. (a) A typical color retinal image without injec. (b) Green component image with green filter applied to color fundus image of (a). (c) Red component image with green filter applied to color fundus image of (a). (d) Blue component image with green filter applied to color fundus image of (a).

For both types of images, a charge coupled device (CCD) video camera is attached to the eyepiece of the fundus camera to make the images collected using the fundus camera available in standard image format. The output from the CCD camera is connected to a PC through image digitizer card. The retinal images were captured to the memory of the computer system. The images were saved on a hard disk for further processing. As for color retinal fundus image, the blue band appears to be very weak and does not contain much information. The vessels appear in red, however the red band usually contains too much noise or is simply saturated since most of the features emit a signal in the red band. On the other hand, the green component of color fundus image gives the blood vessels on a highly contrasted background (darker blood vessels on a bright background). Hence, the green channel of the image is employed in the automated analysis of ocular fundus images. An example of color retinal fundus image and its three color bands components are illustrated in Figure 1.

II. DETECTION OF RETINAL VESSELS

It has been observed that the blood vessels in retinal images have the following three important properties which are useful for vessels analysis [13]:

1. The blood vessels usually have small curvatures and may be approximated by piecewise linear segments.
2. The vessels have lower reflectance compared to other retinal surfaces: they appear darker relative to the background. It is observed that these vessels almost never have ideal step edges. Although the intensity profile varies by a small amount from vessel to vessel, it may be approximated by a Gaussian curve $f(x, y) = A\{1 - k \exp(-d^2 / 2\sigma^2)\}$, where d is the perpendicular distance between the point (x, y) and the straight line passing through the center of the blood vessel in a direction along its length, σ defines

the spread of the intensity profile, A is the gray-level intensity of the local background and k is a measure of reflectance of the blood vessel relative to its neighborhood.

3. The width of a vessel decreases as it travels radially outward from the optic disk and such a change in vessel caliber is a gradual one. Therefore, a vessel is defined as a dark pattern with Gaussian-shape cross-section profile, piecewise connected, and locally linear.

One simple and direct approach to segment objects of interest from background is optimal thresholding with a threshold based on the statistical parameters calculated from the image. Image histogram of distribution of pixel grey-level values is usually used to determine the optimal threshold. Unfortunately, the detection of blood vessels is not straightforward under the complex nature of retinal images. Detection using image statistics does not perform well due to the non-uniform illumination conditions presented in retinal images. Robust and effective studies have been conducted in the area of blood vessel extraction from retinal images. In generally, these studies can be classified into two main categories: detection of blood vessel boundaries and extraction of the core area of the blood vessel tree by tracing vessel centers.

A. Detection of Vessel Edges

An edge is defined as local change or discontinuity in image illumination. The edges in an image provide useful structural information about object boundaries, as the edges are caused by changes in some physical properties of surfaces being photographed, such as illumination, geometry, and reflectance. Thus, edge detection is an essential task in computer vision. It covers a wide range of applications, from segmentation to pattern matching. It reduces the complexity of the image allowing more costly algorithms like object recognition, object matching, object registration to be used. In the case of retinal vessel analysis, the aim of the edge detector is to extract the left and right edges of blood vessel.

A typical example of edge detectors is Sobel operator [14]. The Sobel operator involves the computation of local intensity gradients but the responses due to non-ideal step edges are not good. A modification of that is the detection of second-order zero-crossing with Gaussian noise filtering, and the responding edge operator is called Laplacian of Gaussian [14]. Canny's method is another famous edge detector [15]. Mathematical morphology operations such as morphological gradient enhancement utilizing erosion/dilation can also act as an edge detector in the situations where images are degraded by noise [16, 17].

Edge detectors produce unconnected parallel edges to let extraction of the blood vessel as a whole be still open. These edge techniques have good results only when the edges are sharp and distinct. However, retinal vessels usually have poor local contrast and they almost never have ideal step edges. The application of existing edge detection algorithms yields unsatisfactory results. Moreover, morphological methods often lead to a problem of over-segmentation. Results of edge detection by several edge detectors are shown in Figure 2.

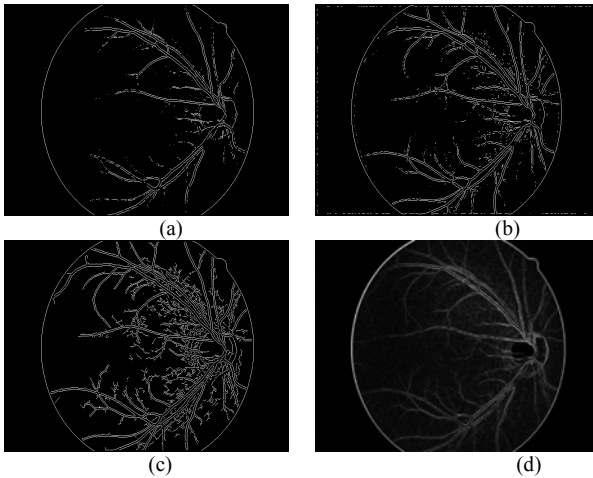


Fig. 2. Edge detection algorithms applied to green image of Fig. 1.(b): (a) Sobel edge detector, (b) LOG edge detector, (c) Canny edge detector, (d) morphological gradient.

Recently some studies performed contour detection using deformable models has been shown to provide more accurate results [18, 19]. Nevertheless, it is not suitable for real-time applications because of its computational complexity and requires user interaction. N. H. Solouma *et al.* [12, 20] propose an algorithm that extracts the blood vessel tree accurately using deformable models and 1-D Gaussian filter with efficient computation. First, the boundaries of vessels are obtained using a simplified form of deformable models. The image is convolved by a Sobel operator in both the horizontal and vertical directions resulting edge values to represent the external energy of the contour. All the neighbouring points of each contour point are searched and points having a value above a certain threshold are extracted as new points on the contour. This process not only deforms the contour but also makes it grow. During the contour iteration, the seed contours that lie within the areas of poor edges shrink until vanishing while the others merge and/or split until recovering a continuous description of all edges that pass above a certain threshold. This process is repeated until no changes occur during a given iteration. Small vessels and the boundaries of large vessels are detected. Then, the core of the wide vessels is determined by correlating the image by a one-dimensional (1-D) Gaussian filter in two perpendicular directions. This reduces the computational complexity of the 2-D matching technique to a great extent and makes it practical for clinical applications.

B. Extraction of the Core of Vessels

The goal of the second category of blood vessel detection in retinal fundus image is to extract the core of blood vessels in retinal fundus images. It can be further divided into two sub-categories in respect to the different processing manners: scanning and tracking [21]. Scanning is typically a two-pass operation. Extraction of core pixels of the blood vessels is conducted by an enhancement-detection process. The desirable image feature points are first enhanced by techniques such as convolving a mask processing with the entire image and then segmented by some convenient thresholding algorithms such as Otsu's global thresholding. In contrast, a tracking operation begins at a *prior* known

positions in the image. In a single-tracing operation, extraction of the image features and recognition of the vessel structure are simultaneously performed by exploiting the three basic properties of the vessel mentioned above.

1) *Scanning*: A method to detect the core of the blood vessels by matching the image by two-dimensional (2-D) Gaussian filters was introduced by S. Chaudhuri *et al.* [22]. Based on the observation that the gray levels across the blood vessel have a Gaussian profile, the grey level profile of the cross section was approximated by a Gaussian-shaped curve and the concept of matched filter detection of signal was used to enhance blood vessels. An inverted, Gaussian-shaped zero-sum matched filter rotated twelve discrete angles of 15 each was designed to detect piecewise linear segment of blood vessels. This filter was performed throughout the retinal image and a threshold was set to differentiate blood vessels from retinal background. This algorithm requires a large number of computations when the filter is applied in 12 different directions for best performance. Moreover this filter tends to get erroneous detection at the boundary of bright objects such as the optical disk and linear background noise resembling to small vessels.

In [23, 24, 25], F. Zana and J. C. Klein presented an algorithm that combines Morphological filters and cross-curvature evaluation to segment vessel-like patterns. Based on fact that blood vessel patterns in retinal fundus images are bright features defined by morphological properties: linearity, connectivity and curvature of vessels varying smoothly along the crest line, mathematical morphology was used to highlight vessels with respect to their morphological properties. However other patterns fit such a morphological description. In order to differentiate vessels from analogous background patterns, a cross-curvature evaluation is performed. Vessels are detected as the only features whose curvature is linearly coherent. The detection algorithm that derives directly from this modeling is based on four steps: 1) noise reduction; 2) linear pattern with Gaussian-like profile improvement; 3) cross-curvature evaluation; 4) linear filtering. The algorithm had been tested on retinal photographs of three different types: fluoroangiography, gray images obtained with a green filter, and color images with no filter. Occasionally a short preprocessing step was necessary since the algorithm only works with bright patterns in gray level images.

M. E. Martinez-Perez *et al.* [26, 27] propose that blood vessels are segmented based on multi-scale analysis. Two geometrical features based upon the first and the second derivative of the intensity image, maximum gradient and principal curvature, is obtained at different scales by means of Gaussian derivative operators. A multiple pass region growing procedure is used which progressively segments the blood vessels using the feature information together with spatial information about the eight-neighboring pixels. The algorithm works with red-free as well as fluorescein retinal images.

Nekovei and Sun [28] describe an approach using back-propagation network for the detection of blood vessels in X-ray angiography. The method applies the neural network directly to the angiogram pixels without prior feature detection. Since angiograms are typically very large, the

network is applied to a small sub-window which slides across the angiogram. The pixels of the sub-window are directly fed as input to the network. Pre-labeled angiograms are used as the training set to set the network's weights. A modified version the common delta-rule is to obtain these weights. The proposed method does not extract the vascular structure but is to label the pixels as vessel or non-vessel.

Francis K. H. Quek *et al.* [29] present an approach for the extraction of vasculature from angiography images by using a wave propagation and traceback mechanism. Each pixel is labeled in an angiogram with the likelihood that it is within a vessel by using a dual-sigmoidal filter. Representing the reciprocal of this likelihood image as an array of refractive indexes, a digital wave is then propagated through the image from the base of the vascular tree. This wave "washes" over the vasculature, ignoring local noise perturbations. The extraction of the vasculature becomes that of tracing the wave along the local normals to the waveform. An efficient sequential algorithm for the wave propagation is presented in the reference. Wave propagation and traceback allows to extract not only the individual vessels, but the vascular connection morphology as well.

Tianhu Lei *et al.* [30, 31, 32] present a near-automatic process for separating vessels from background and other clutter as well as for separating arteries and veins in contrast-enhanced magnetic resonance angiographic (CE-MRA) image data. The separation process utilizes fuzzy connected object delineation principles and algorithms. After seed voxels are specified inside artery and vein in the CE-MRA image, the small regions of the bigger aspects of artery and vein are separated in the initial iterations, and further detailed aspects of artery and vein are included in later iterations. The algorithm is able to separate higher order branches, and therefore produces vastly more details in the segmented vascular structure. However, seed voxels have to be manually specified inside artery and vein objects by an operator interactively during the process.

Other techniques using steerable filters have also been used in the detection of the blood vessel core [33, 34]. This class of filters is not applied in many directions. Rather, it is applied in only two basic directions and the response is calculated in other directions from a combination of the responses from these two directions. This has the advantage of faster computation for a reasonable accuracy.

The scanning methods search throughout the whole image for possible feature pixels, they usually provide complete segmentation of the blood vessels in the image. However, the thorough scanning over the whole image is very computationally intensive and requires more time and space. Moreover, the existence of random or structural noise which has also been enhanced in the first stage may bewilder the recognition of blood vessel network in the second stage and lead to erroneous results. On the other hand, the tracking methods are inherently efficient computation and can always provide a meaningful description of the vessel network. The disadvantages is that it is insufficient to provide a complete segmentation in the case the blood vessel fades away in the middle part and emerges again in its extended direction. This can be alleviated to some degree by estimating along the direction when the blood vessel seems to end.

2) *Tracking*: Zhou, *et al.* [35] develop an algorithm to track the midline and extract diameters and tortuosity of a single vessel segment, although only diameter measurements are reported. The tracking of a blood vessel proceeds by extending the search in the direction of the last-tracked part of the blood vessel by a certain fixed length. The density profile on the perpendicular line in the extended direction is taken and a Gaussian matched filter is convolved with it and the result is examined. The strategy is to estimate the next location based on the current location, observe the next actual location by the matched filter, correct the estimation and then re-estimate the next location and continue iteratively. Moreover, the matched filter helps ignoring small branches at a bifurcation point without any special handling, thus allowing the tracking process to follow one major branch continuously. However, the algorithm needs starting and ending points and a tracking direction defined by an operator.

Liu and Sun [36, 37] present an approach that extracts extended tracts of vasculature in X-ray angiograms by an adaptive tracking algorithm. Given an initial point within a vessel, they apply an "extrapolation update" scheme that involves the estimation of local vessel trajectories. Once a segment has been tracked, it is deleted in the angiogram image by growing the "deletion intensity value" over the grey levels representing the vessel. This procedure is performed recursively to extract the vascular tree. This algorithm also requires the user to specify vessel starting points.

In L. Gang and O. Chutatape [38, 39], the fitness of estimating vessel profiles with Gaussian function is evaluated and an amplitude modified second-order Gaussian filter is proposed for the detection and measurement of vessels. It proves that the vessel width can be measured in linear relationship with the "spreading factor" of the matched Gaussian filter when the magnitude coefficient of the Gaussian filter is suitably assigned. The vessel width measurement not only provides the size of blood vessel but it is also useful for optimizing the matched filter to improve the successful rate of detection. In another reference by Opas Chutatape *et al.* [21] using tracking strategy for blood vessels detection in retinal fundus images, the Kalman filter is employed to estimate the next vessel segment location using not only the parameters of current segment but all previous vessel segments as well similar to tracking a flying object in the radar system. A Gaussian matched filter then locals the actual centerline midpoint based on the cross-section density profile at the estimated incremental section. The look-ahead distance and the searching window size are decided based on the error estimation of the Kalman filter. Instead of specifying points for the tracking to start by operators, the method uses the second order derivative of Gaussian filter to convolve with the density profile of a starting circle already detected such as optic disk where all vessels originate. The local maxima with high response are selected as the starting points of major vessels for the tracing algorithm to work. It seems the use Kalman filter posing a large amount of computation and the improvement in performance is not as obvious.

III. IMPLEMENTATION OF TWO VESSELS DETECTION ALGORITHMS

F. Zana and J.C. Klein [23] present an algorithm that combines Morphological filters and cross-curvature evaluation to segment blood vessels in retinal angiographies. Vessel-like patterns are bright features defined by morphological properties: linearity, connectivity, width and by a specific Gaussian-like profile whose curvature varies smoothly along the crest line. Mathematical Morphology is very well adapted to this description and is used to highlight vessels with respect to their morphological properties. However other patterns fit such a morphological description. In order to differentiate vessels from analogous background patterns, a cross-curvature evaluation is performed. Vessels are detected as the only features whose curvature is linearly coherent. This algorithm has been tested on retinal photographs of three different types: fluoroangiography, gray images obtained with a green filter, and color images with no filter. Occasionally a short preprocessing step was necessary since the algorithm only works with bright patterns in gray level images.

The detection algorithm is based on four steps. 1) noise reduction: small bright noise is removed while most of the capillaries are preserved using a geodesic reconstruction of the opened images into the original image. The structure size is approximately the range of the diameter of the biggest vessels.

$$S_{op} = \gamma_{S_o}^{rec} (Max_{i=1..12} \{\gamma_{L_i}(S_o)\})$$

2) linear pattern with Gaussian-like profile improvement: the sum of tophats on the filtered image will enhance all vessels whatever their direction, including small or tortuous vessels, even in the low signal. The large homogeneous pathological areas will be set to zero since they are unchanged by the tophat operation. Vessels could be manually segmented with a simple threshold on. However the image contains a lot of details corresponding to background linear features that are also enhanced by the difference. Figure 3 shows the results of blood vessel enhancement applied by the morphological operations.

$$S_{sum} = \sum_{i=1}^{12} (S_{op} - \gamma_{L_i}(S_o))$$

3) cross-curvature evaluation: the result of sum of tophat still contain noisy data requiring further treatment. The noise tends to be low and disorganized whose curvature will have alternating positive and negative values in various directions. Hence, the sign of the Laplacian can be used as a good approximation of the sign of the curvature. However, in a few cases, this fuzzy signal can have a curvature that looks very much like a small vessel. The proposed strategy does not separate this signal from the retinal vessels, leading to false detection.

$$S_{lap} = Laplacian(Gaussian_{\sigma=7/4}^{width=7px}(S_{sum}))$$

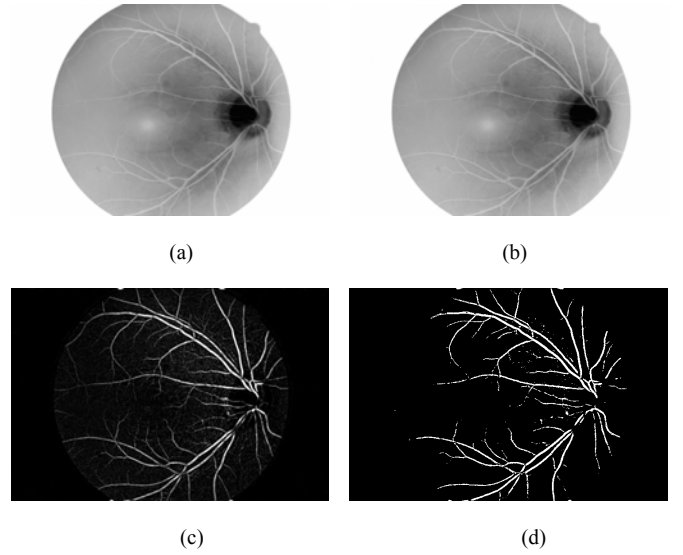


Fig. 3. Each step of the morphological treatment: (a) original image of inverted version of the image given in Fig. 1 (b) image, (b) supremum of opening, (c) reconstruction, and (d) sum of tophat.

4) linear filtering: after computing the Laplacian which is a good estimation of the curvature, the alternating filter is applied to make the final result. The alternating filter contains a linear opening by reconstruction, a linear closing by reconstruction and finally a linear opening of larger size. This alternating filter removes most of the enhanced noise patterns. The structure element sizes should be adjusted to the sizes of the vessel patterns for specific application. Figure 5 and Figure 6 give the results of curvature computation and final result of blood vessel detection.

$$S_1 = \gamma_{S_{lap}}^{rec} (Max_{i=1..12} \{\gamma_{L_i}(S_{lap})\})$$

$$S_2 = \gamma_{S_1}^{rec} (Min_{i=1..12} \{\phi_{L_i}(S_1)\})$$

$$S_{res} = (Max_{i=1..12} \{\gamma_{L_i}^2(S_2)\} \geq 1)$$

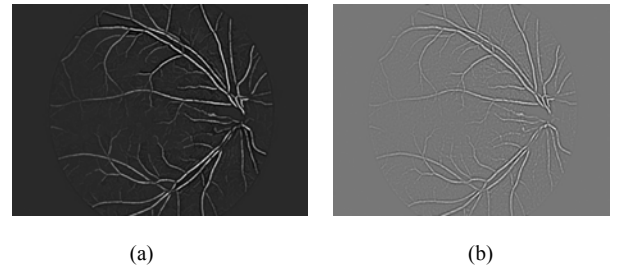


Fig. 4. Laplacian images highlighted around zero (positive values in white and negatives in black) before (a) and after the alternating filter (b).

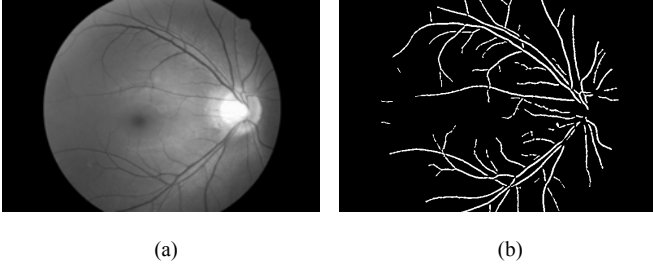


Fig. 5. segmentation results by mathematical morphology and curvature evaluation (a) original retinal fundus image, (b) extracted blood vessel tree.

S. Chaudhuri *et al.* [13] propose a method to detect the core of the blood vessels by matching the image by two-dimensional (2-D) Gaussian filters. The rationale is that the gray levels across the blood vessel have a Gaussian profile. The matched filter was able to enhance blood vessels to make them readily be differentiated from background by conveniently adapting a thresholding algorithm such as Otsu's method. Based on the observations that vessels may be considered as piecewise linear segments, matching a number of cross sections along its length simultaneously was developed to improve detection performance instead of matching a single intensity profile of the cross section of a vessel. For vessels at different orientations, the Gaussian filter has to be rotated accordingly. Detailed implementation of the method is as follows.

The two-dimensional matched filter kernel in a discrete grid is designed as follows. Let $\overline{p} = [x \ y]$ be a discrete point in the kernel and θ_i be the orientation of the i th kernel matched to a vessel at an angle θ_i . in order to compute the weighing coefficients for the kernel, it is assumed to be centered about the origin $[0 \ 0]$. The rotation matrix is given by

$$\overline{r}_i = \begin{bmatrix} \cos \theta_i & -\sin \theta_i \\ \sin \theta_i & \cos \theta_i \end{bmatrix}$$

and the corresponding point in the rotated coordinate system is given by $\overline{p}_i = [u \ v] = \overline{p} \overline{r}_i^T$. Assuming an angular resolution of 15 degree, 12 different kernels are needed to span all possible orientations. Then a set of 12 such kernels applied to a retinal fundus image and at each pixel only the maximum of their responses is retained.

A Gaussian curve has infinitely long double sided trails. The trail is truncated at $u = \pm 3\sigma$. A neighborhood N is defined such that $N = \{(u, v) \mid |u| \leq 3\sigma, |v| \leq L/2\}$. L is the length of the segment for which the vessel is assumed to have a fixed orientation. L is used to be experimentally determined. The corresponding weighs in the i th kernel of the proposed 2-D Gaussian filter are given by

$$K_i(x, y) = -\exp(-x^2 / 2\sigma^2) \quad \forall p_i \in N$$

Consider the response of this filter for a pixel belonging to the background retina. Assuming the background to have

constant intensity with zero mean additive Gaussian white noise, the expected value of the filter output should ideally be zero. The convolution kernel is, therefore, modified by subtracting the mean values from the function itself. If A denotes the number of points in N , the mean value of the kernel is determined as

$$m_i = \sum_{p_i \in N} K_i(x, y) / A$$

Thus, the convolution mask of 2-D Gaussian matched filter used to detect blood vessels is finally given by,

$$K'_i(x, y) = K_i(x, y) - m_i \quad \forall p_i \in N.$$

Two of the 12 different kernels that have been used to detect vessel segments along different orientation are given in Figure 6. Final segmentation result of blood vessel by the matched filter is shown in Figure7.




Fig. 6. Two of the 12 different kernels that have been used to detect vessel segments along different orientation: (a) segments along the 45 degree direction, (b) segments along the vertical direction. $\sigma = 2.0$ and $L = 9$.

The matching filter algorithm [13] produces an image of good quality for the biggest vessels, however some smaller vessels of poor contrast are only partially detected. The method in deed gets some response due to edges of other bright objects such as optic disk due to the fact that the local contrast is very high and the edge of the objects partially match the shape of the Gaussian kernel. Moreover, linear background noise is also enhanced by the designed filter and segmented as blood vessels. A post-processing step is needed to identify and subsequently eliminate such false detection. Mathematical morphology transformations are known to be sensitive to changes of scale. Since a large part of the method proposed in [23] employs morphological operations, scale effects cannot be avoided. However, the algorithm has proved to be efficient on a wide scale of Gaussian profiles due to the reconstruction procedure. The scale effect is encountered in two parts of the algorithm: 1) during the sum of top hats, big vessels are excluded when their profiles are larger than the first structuring element and 2) during the very last opening, vessels that are not longer than the last structuring element or that appear tortuous compared to this structuring element are removed. Linear background structure resembling small vessels is also detected. Small vessels appear wider than their real size due to the Gaussian filter that is used before computation of the Laplacian. Both

methods give good segmentation of big vessels while mathematical morphology approach produces more detailed description of the blood vessel tree structure. The vessel detection results are accurate and sufficient for some applications such as registration. On the other hand, they do not provide a meaningful description of the vessel network and parameters of vessels such as vessel calibre for analysis of vessel abnormality which have to be measured through other designed methods.

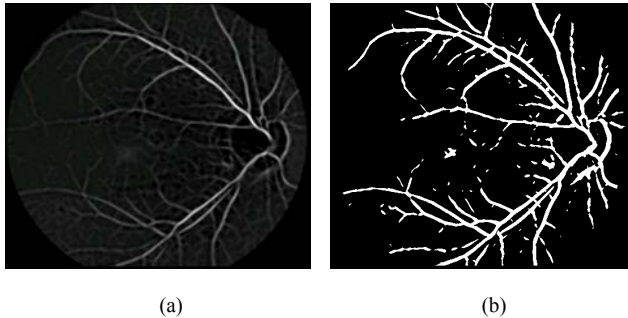


Fig. 7. Result of application of the matched filter to the image given in Fig. 1(b): (a) enhanced blood vessels with 2-D Gaussian matched filter, (b) binary blood vessel tree by Otsu's thresholding method.

IV. CONCLUSION AND DISCUSSIONS

Ocular fundus image can provide information on pathological changes caused by local ocular diseases and early signs of certain systemic diseases. Blood vessels are useful in revealing the states of diseases in the form of measurable abnormalities such as length of diameter and degree of tortuosity in the blood vessels. In addition, they can also act as landmarks for image-guided laser treatment of choroidal neovascularization. Thus, reliable automatic detection of blood vessel that preserves various vessel measurements is needed.

Methods for segmentation of blood vessel can be mainly classified into two categories: detection of blood vessel boundaries and extraction of the core area of the blood vessel. Since blood vessels in retinal images almost never have ideal step edges and a large amount of noise with sharp boundaries exist, application of existing edge detection algorithms yields unsatisfactory results to make them rarely be employed in both research and practice. Fig. 2. illustrates the situation. On the other hand, segmentation of the core of the blood vessel proves to be accurate and effective for detection of blood vessel structure in retinal fundus images. The scanning approaches search throughout the whole image for possible feature pixels, they usually provide complete segmentation of the blood vessels in the image. However, the thorough scanning over the whole image is very computationally intensive and requires more time and space. Moreover, the existence of random or structural noise also leads to erroneous results. On the other hand, the tracking approaches are inherently efficient computation and can always provide a meaningful description of the vessel network. One disadvantage of the tracking method is that it usually needs operator to specify starting parameters

interactively to initiate the tracking process. A prior knowledge that blood vessels are outwards around optic disk makes the recognition of optic disk a premise for automatic tracking. The tracking method is also unable to provide a complete segmentation in the case the blood vessel fades away in the middle part and emerges again in its extended direction. The specific method adopted in detection of blood vessel is application-oriented. For example, scanning approaches to segment the core of blood vessel have results that are accurate and sufficient for registration application. Nevertheless, they do not provide any parameters of vessels such as vessel calibre for analysis of vessel abnormality which have to be measured through other designed methods. In such situation the tracking operation can simultaneously perform extraction of the vessel features and recognition of the vessel structure.

Existing strategies for artery and vein separation are based on various measurement of pixels properties such as grey-scale intensity value obtained from green images or color transformation. Careful observation of red component image of color fundus image reveals that artery expresses themselves quite clear while vein is almost invisible as shown in Figure 1. This prompts the feasibility of artery and vein separation on red images provided that color fundus images are available and the whole blood vessel tree has being segmented from background.

REFERENCES

- [1] American Academy of Ophthalmology, "Retina and vitreous," *Basic and Clinical Science Course*, section 11, pp. 13-27, 31-39, 1991.
- [2] Macular Degeneration Study Group, "Recurrent choroidal neovascularization after argon laser photocoagulation for neovascular maculopathy," *Arch. Ophthalmol.*, vol. 104, pp. 503-12, 1986.
- [3] K. H. Lim, "Registration of New Blindness in Singapore for 1985-1995," *Singapore Medical Journal*, vol. 40, no. 2, Feb 1999.
- [4] L. G. Goh, "A Diabetes Centre In The Community," *Singapore Medical Journal*, vol. 30, no. 3, Mar 1998.
- [5] H. A. Kahn, R. Hiller, "Blindness caused by diabetic retinopathy," *Am. J. Ophthalm.*, vol. 78, pp. 58-67, 1974.
- [6] P. F. Palmberg, "Diabetic Retinopathy," *Diabetes*, vol. 26, pp.703-709, 1977.
- [7] R. Klein, B. Klein, S. E. Moss, K. J. Cruickshanks, "The Wisconsin Epidemiologic study of diabetic retinopathy. XV. The long term incidence of macular edema," *Ophthalm.*, vol. 102, pp.7-16, 1995.
- [8] J. C. Javitt, J. K. Canner, A. Sommer, "Cost effectiveness of current approaches to the control of retinopathy in type I diabetics," *Ophthalm.*, vol. 96, pp.255-264, 1989.
- [9] I. S. Ghafour, D. Allan, W. S. Foulds, "Common causes and blindness and visual handicap in the west of Scotland," *Brit. J. Ophthalm.*, vol. 67, pp.209, 1983.
- [10] D. E. Singer, D. M. Nathan, H. A. Fogel, A. P. Schachar, "Screening for diabetic retinopathy," *Ann. Intern. Med.*, no. 116, pp. 660-671, 1992.
- [11] Macular Degeneration Study Group, "Recurrent choroidal neovascularization after argon laser photocoagulation for neovascular maculopathy," *Arch. Ophthalmol.*, vol. 104, pp. 503-12, 1986.
- [12] Nahed H. Solouma, Abou-Bakr M. Youssef, Yehia A. Badr, and Yasser M. Kadah, "A New Real-Time Retinal Tracking System for Image-Guided Laser Treatment," *IEEE Trans. Biomedical Engineering*, vol. 49, no. 9, pp.1059-1067.
- [13] S. Chaudhuri, S. Chatterjee, N. Katz, M. Nelson, M. Goldbaum, "Detection of Blood Vessels in Retinal Images Using Two-Dimensional Matched Filters," *IEEE Trans. on Med Imag* 1989, vol 8, no. 3, pp. 263-269.
- [14] W. Pratt, *Digital Image Processing*. New York: Wiley, 1978.

- [15] J. F. Canny, "A computational approach to edge detection," *IEEE Trans. Pattern Anal. Machine Intell.*, vol. PAMI-8, pp. 679–698, 1986.
- [16] F. Meyer and S. Beuchar, "Morphological segmentation," *J. Vis. Commun. Imag. Representation*, vol. 1, no. 1, pp. 21–46, 1990.
- [17] R. M. Haralick, S. R. Sternberg, and X. Zhuang, "Image analysis using mathematical morphology," *IEEE Trans. Pattern Anal. Machine Intell.*, vol. 9, pp. 532–550, Apr. 1987.
- [18] T. McInerney and D. Terzopoulos, "Deformable models in medical image analysis: A survey," *Med Image Anal.*, vol. 1, no. 2, pp. 91–108, 1996.
- [19] T. McInerney and D. Terzopoulos, "Topologically adaptable snakes," in *Proc. Int. Conf. Computer Vision (ICCV)*, June 1995, p. 840.
- [20] Nahed H. Solouma, Abou-Bakr M. Youssef, Yehia A. Badr, and Yasser M. Kadah, "Robust computer-assisted laser treatment using real-time retinal tracking" in *Proceedings of the 23rd Annual International Conference of the IEEE*, vol. 3, 2001, pp. 2499–2502.
- [21] O. Chutatape, Liu Zheng, S. Krishnan, "Retinal Blood Vessel Detection and Tracking by Matched Gaussian and Kalman Filters," in *Proceeding of IEEE Int Conf Eng and Bio Society*, 1998, vol. 20, no. 6, pp. 3144-3149.
- [22] S. Chaudhuri, S. Chatterjee, N. Katz, M. Nelson, M. Goldbaum, "Detection of Blood Vessels in Retinal Images Using Two-Dimensional Matched Filters," *IEEE Transactions on Med Imag*, vol. 8, no. 3, pp. 263-269.
- [23] F. Zana, F. and J.C. Klein, "Segmentation of vessel-like patterns using mathematical morphology and curvature evaluation," *IEEE Trans. Image Processing*, vol. 10, no.7, pp.1010-1019.
- [24] F. Zana, J. C. Klein, "A Multimodal Registration Algorithm of Eye Fundus Images Using Vessels Detection and Hough Transform," *IEEE Trans. Med Imag*, 1999, vol. 18, No. 5, pp. 419-428.
- [25] F. Zana, J. C. Klein, "Robust segmentation of vessels from retinal angiography," in *Proc. Int. Conf. Digital Signal Processing*, 1997, pp. 087-1090.
- [26] M.E. Martinez-Perez, A. D. Highes, A. V. Stanton, S. A. Thorn, N. Chapman, A. A. Bharath, K. H. Parker, "Segmentation of retinal blood vessels based on the second directional derivative and region growing," in *Proc. ICIP 99*, vol. 2, pp. 173–176.
- [27] M.E. Martinez-Perez, A. D. Highes, A. V. Stanton, S. A. Thorn, N. Chapman, A. A. Bharath, K. H. Parker, "Retinal vascular tree morphology: a semi-automatic quantification," *IEEE Trans. Biomedical Engineering*, vol. 49, no. 8, Aug. 2002, pp. 912–917.
- [28] R. Nekovei and Y. Sun, "Back-propagation network and its configuration for blood vessel detection in angiograms," *IEEE Trans. Neural Net-works*, vol. 6, pp. 64–72, Jan. 1995.
- [29] F. K. H. Quek and C. Kirbas, "Vessel Extraction in Medical Images by Wave-Propagation and Traceback," *IEEE Trans. Biomedical Engineering*, vol. 49, no. 9, 2002, pp.117-131.
- [30] Tianhu Lei, J. K. Udupa, P. K. Saha and D. Odhner, "Artery–Vein Separation via MRA—An Image Processing Approach," *IEEE Tran. Medical Imaging*, vol. 20, no. 8, 2001, pp. 689-703.
- [31] T. Lei, J. K. Udupa, P. K. Saha, and D. Odhner, "3-D MR angiographic visualization and artery–vein separation," *SPIE Proc.*, vol. 3658, pp. 52–59, 1999.
- [32] T. Lei, J. K. Udupa, P. K. Saha, D. Odhner, and R. Baum, "Artery–vein separation using MR angiographic data: In 25 patients," in *Proc. ISMRM*, vol. 3, 1999, p. 1235.
- [33] W. T. Freeman and E. H. Adelson, "The design and use of steerable filters," *IEEE Trans. Pattern Anal. Machine Intell.*, vol. 13, pp. 891–906, Sept. 1991.
- [34] B. Kochner, D. Schuhmann, M. Michaelis, G. Mann, and K. H. Englmeier, "Course tracking and contour extraction of retinal vessels from color fundus photographs: Most efficient use of steerable filters for model based image analysis," in *SPIE Conf. Image Processing*, vol. 3338, 1998, pp. 755–761.
- [35] L. Zhou, M. S. Rzeszotarski, L. J. Singerman, and J. M. Chokreff, "The detection and quantification of retinopathy using digital angiograms," *IEEE Trans. Med. Imag.*, vol. 13, pp. 619–626, Dec. 1994.
- [36] I. Liu and Y. Sun, "Recursive tracking of vascular networks in angiograms based on the detection-deletion scheme," *IEEE Trans. Medical Imagong*, vol. 12, pp. 334–341, June 1993.
- [37] Y. Sun, "Automated identification of vessel contours in coronary arteriograms by an adaptive tracking algorithm," *IEEE Trans. Medical Imaging.*, vol. 8, pp. 78–88, Mar. 1989.
- [38] L. Gang, O. Chutatape, and S. M. Krishnan, "Detection and Measurement of Retinal Vessels in Fundus Images Using Amplitude Modified Second-Order Gaussian Filter," *IEEE Tran. Biomedical Engineering*, 2002, vol. 49, no. 2, pp. 168-172.
- [39] Luo, G., Chutatape, O., Krishnan, S., "Performance of Amplitude Modified Second Order Gaussian Filter for the Detection of Retinal Blood Vessel," in *Proc SPIE*, vol 4245, Ophthalmic Technologies XI 2001, pp. 164-169.